

Review Article

Surgical Challenges in the Management of Advanced Osteoradionecrosis of the Mandible

Jacob D'Souza^{1*}, Martin Batstone² and Simon Rogers^{3,4}

¹Maxillofacial Unit, Royal Surrey County Hospital, UK

²Maxillofacial Unit, Royal Brisbane Hospital, Australia

³Regional Maxillofacial Unit, Aintree University Hospital, UK

⁴Evidence-Based Practice Research Centre (EPRC), Edge Hill University, UK

***Corresponding author:** Jacob D'Souza, Maxillofacial/Head & Neck Surgeon, Royal Surrey County Hospital, Egerton Road, Guildford, GU2 7XX, UK, Tel: +447748843036; Fax: +441483406647; Email: dsouzaj@icloud.com

Received: February 12, 2015; **Accepted:** March 24, 2015; **Published:** March 26, 2015

Abstract

Advanced Osteoradionecrosis is a severe problem associated with complex oro-cutaneous damage and pathological fracture. The morbidity is significant, both in terms of aesthetics and function, with detrimental consequences on the quality of life. The mainstay of treatment for advanced ORN is radical surgery involving free tissue transfer. The challenging nature of such reconstructive surgery is set out in the context of a patient previously treated for cancer, whether surgery and radiotherapy or chemoradiotherapy, and therefore significant comorbidities. The clinician is thus presented with challenging decisions to be made with regards to conservative vs. radical treatment of these patients and the choice of reconstruction.

The aim of this paper is to highlight the difficulties encountered in the decision-making process and the reconstructive challenges of ORN, reflecting on the experience of the authors at the three international centres. For the ease of description, we have divided the problems and solutions encountered into eight different sections.

1. Patient characteristics, pre-operative planning and medical optimisation.
2. Vessel depleted neck and the choice of neck vessels.
3. Soft tissues defect and management of the fistula.
4. Reconstruction of the bone.
5. Choice of plates.
6. Choice of flaps.
7. Expertise of the unit.
8. Outcomes.

Keywords: Osteoradionecrosis; Free flap; Vascular access; Soft tissue; Bone; Plates; Reconstruction

Introduction

Osteoradionecrosis (ORN) may be defined as 'exposed and necrotic bone associated with ulcerated or necrotic soft tissue which persists for greater than 3 months in an area that had been previously irradiated, and not caused by tumour recurrence' [1]. The risk for developing ORN is life-long, but the majority of cases develop within the first 2 years following radiotherapy (RT) [2,3]. The incidence of ORN is higher in the mandible, especially the dentate mandible [1,2,4]. The progressive loss of soft and hard tissues has adverse effects on the quality of life (QOL). The management of ORN, be it conservative or surgical, is a major challenge. Surgical intervention should be considered in the context of the patient's medical co-morbidities and social situation. The extent of surgical resection should prevent the unfavourable outcome of non-union, risk of plate infection and progressive ORN. Of further significance is often the lack of suitable vessels in the neck, both in terms of availability and adequate diameter and free flap (FF) donor sites [5,6]. A multi-disciplinary team (MDT) approach, led by an experienced reconstructive surgeon is mandatory in achieving a favourable outcome. The purpose of

this paper is to share our experience from three major international centres, the difficulties encountered in the decision-making process and surgery, focusing especially on reconstruction. The centres are University Hospital Aintree, Liverpool, UK; Royal Surrey County Hospital, Guildford, UK and Royal Brisbane Hospital, Brisbane, Australia (Table 1).

Patient characteristics, pre-operative planning and medical optimization

The risk factors implicated in the development of the primary malignancy are often persistent and their negative impact on health is at a more advanced stage in patients with ORN. Advancing age, unfavourable life-style habits and social deprivation serve only to complicate the management of these medically and functionally compromised patients [7,8]. Sadly, these factors are seen in patients who are perhaps just beginning to feel optimistic of their outcomes from the morbidity of radical surgery and/or chemoradiation for the primary malignancy. And they adversely affect the quality of vessels due to progressive atheroma, both in the neck and free flap donor sites. There is also the added risk of aspiration and pneumonia.

Table 1: Summary of selected cases from the three regional centers and their outcomes.

Composite free flap and fixation	No. of cases	No. of plates removed	Outcome of Osteoradionecrosis
Radial, miniplate	2	1	Healed
Radial, reconstruction plate	11	4	3 non-union
Fibula, miniplate	7	2	2 non-union
Fibula, reconstruction plate	23	1	2 non-union
Deep Circumflex Iliac Artery, miniplate	11	3	Healed
Deep Circumflex Iliac Artery, reconstruction plate	4	3	1 non-union
Deep Circumflex Iliac Artery, unknown plate type	5	0	1 non-union
Scapula, miniplate	4		2 non-union
Scapula, reconstruction plate	6	0	Healed

Source of data: University Hospital Aintree, Liverpool, UK; Royal Surrey County Hospital, Guildford, UK and Royal Brisbane Hospital, Brisbane, Australia.

High-risk patients spend a longer time in intensive care units and are responsible for more than 80% of postoperative deaths [9,10]. Assessment of the patient's life-style habits, nutrition, anaemia, cardiovascular status and other medical conditions aim to reduce the systemic response to surgery and enhance recovery. Therefore, preoperative medical optimization is key to good outcome in the surgical management of the ORN patient.

Cessation of smoking and alcohol intake pre-operatively significantly reduces the risk of wound infection, impaired healing and cardiopulmonary complications in the post-operative phase. The duration of these interventions for maximal benefit can be between 3 and 8 weeks [11], and this is possible in patients with ORN who usually have elective surgery. Prophylaxis against, and prompt management of alcohol withdrawal symptoms is important to improve surgical outcomes.

Nutritional deficiency may be due to social factors or morbidity from previous treatment of the primary malignancy resulting in trismus, dysphagia and odynophagia. It significantly increases both infectious and non-infectious complications such as re-feeding syndrome following surgery [12]. Nutritional support preoperatively for 7-10 days has been shown to reduce postoperative morbidity, length of stay and mortality [13,14]. Enteral nutrition should take preference over parenteral nutrition since it is safer, more physiological, less expensive and practicable at home. Percutaneous or radiologically inserted gastrostomy feeding tube will ensure feeding both pre- and postoperatively.

Preoperative correction of anaemia should be preferably done by noninvasive modalities such as dietary advice and iron supplements, in conjunction with input from dieticians, physicians and the primary care. This is possible in the patients with ORN since the timing of surgery is elective. Haemoglobin level of below 10 g/dL is often regarded as the minimum threshold for intervention. Post-operatively, a haemoglobin range of 8-10g/dl is desirable in the context of free flap surgery. Decision for blood transfusion should be taken on the basis of individual patient's needs and wishes, and the potential for complications such as transmission of infections, increased risk of post-operative infections and the immunosuppressant effect of transfusion [15].

Cardio-respiratory risk in should be assessed preoperatively by a structured history and examination, for instance by measuring

'functional capacity'. Optimization of blood pressure, beta blockade, coronary revascularization, modifications to anaesthesia and perioperative monitoring techniques should be considered [16]. Deep breathing exercises, bronchodilators and early mobilization help prevent atelectasis and its sequelae [17]. Patients taking ACE inhibitors and angiotensin II receptor antagonists are a higher risk of intra-operative hypotension. This has implications such as lack of flap perfusion and the requirement for inotropic support with potential for flap compromise. This mandates the involvement of an experienced anaesthetist in the work up of patients with ORN.

Poor blood glucose control in the perioperative period is an independent predictor of infection and mortality, independent of the diabetic status [16]. Mortality rates in diabetic patients following major surgery are estimated to be up to five times greater than in non-diabetic patients [18]. Microangiopathy can potentially reduce the availability of the flap donor sites and the flap success rates.

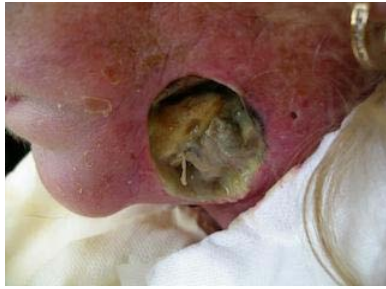The psychological and physical stress, depression and potential low-esteem among patients with advanced ORN should prompt the involvement of a clinical psychologist. The indication for surgery in ORN is not necessarily for aesthetic and functional rehabilitation, in many circumstances, reconstruction simply aims to control pain, halitosis, oro-cutaneous fistula, improve trismus and oral intake, all of which can significantly improve patients QOL and their ability to socialize once again. Comprehensive preoperative assessment therefore facilitates postoperative recovery, reduces anxiety and pain, and improves postoperative self-care and symptom management [19].

Vessel depleted neck and the choice of neck vessels

Treatment for cancer with surgery and/or RT results in a vessel depleted neck, both in terms of availability and suitable caliber of vessels, adding to the challenges of reconstruction of the ORN defect [6,20,21]. RT damage to carotid vessels and its branches resulting in atherosclerosis, stenosis and increased risk of neurological sequelae, such as stroke and transient ischaemic attack are well documented [22,23]. One should remain optimistic, however, since despite potential difficulties, comparable outcomes in terms of complications and free flap success rates for ORN compared to patients who undergo free flap reconstruction for other indications have been reported [24].

Arterial

In the previously unoperated neck, the facial artery, faciolingual



Case 1: Patient with significant medical co-morbidities and a complex defect.

trunk and superior thyroid arteries are most commonly used for anastomoses. In patients with ORN, these vessels may be damaged, ligated, lack pedicle length, utilized in the previous free flap and/or be affected by RT damage. Therefore, both their availability and suitability of caliber to provide adequate run off can be suspect. Furthermore, the discrepancy in caliber between the donor and the neck vessels tends to be more pronounced in the ORN patients due to effects of RT and the situation demanding the use of vessels with smaller caliber such as the transverse cervical artery [21-23]. The relationship between the hypoglossal nerve and the posterior belly of the digastric muscle is an important landmark for locating the branches of the external carotid artery (ECA). Distortion of the neck anatomy from fibrosis as a result of RT or recurrent infection makes intra-operative dissection, especially of the hypoglossal nerve and IJV difficult, risking injury and unintended perforations. In our institutions, we circumvent this problem carefully dissecting along the carotid system, identifying the ECA and then its branches. We often divide the digastric muscle to facilitate turning down the ECA to facilitate increase in its length. There is often the need to seek for alternatives vessel such as the transverse cervical or internal mammary or the contralateral neck vessels. Hanasono et al. [25] publishing on their experience of microvascular surgery in the previously operated neck reported the need to seek vessels other than the external carotid arterial system in 19% of cases. The use of contralateral neck vessels in 61% patients who had a prior neck dissection has been reported by Head et al. [26]. This mandates the need for sufficient length of the pedicle of the donor flap, thus limiting the availability of donor sites to perhaps to composite radial or a fibula free flap. The successful use of pedicle of the existing free flap is well documented [27,28], and has been used by the authors of this paper. The root of the neck can be explored and in one study [29] comprising 33 neck explorations, suitable transverse cervical vessels were found in 92% cases. In the author's experience, this vessel is a reasonable size match for the radial forearm free flap (RFFF) that affords a long pedicle for anastomoses low in the neck. Of great advantage is that the transverse cervical vessels are spared from radiation damage, since the supraclavicular fossa is usually outside the RT field. Other, but more challenging options include the thoraco-acromial and the internal mammary arterial systems [20,30]. The authors have experience in the use of internal mammary vessels. Exposure of the vessel was achieved by the removal of 2nd or 3rd costal cartilage after division of the pectoralis muscle, with the vessel seen just deep to the perichondrium. However, the disadvantages such as the need for additional donor site, risk of pedicle compression within the subcutaneous tunnel from the chest to the neck, and the potential need for vein grafts to reach most

head & neck sites. The involvement of a cardio-thoracic surgeon is essential and this is a high-morbidity procedure with a prolonged phase of post-operative recovery and risk of pneumonias. The use of vein grafts, arterial-venous loops and the transposition of cephalic or thoraco-dorsal vessels have all been reported with varying degrees of success, but may be associated with higher rates of failed anastomosis [31-33]. The authors have no experience in this regard. Finally, the use of duplex or angiography preoperatively for mapping of the neck vessels is used by some clinicians [34,35].

Venous

The internal jugular vein (IJV) is reliable, due to size, constant anatomy, high patency rates, potential for multiple anastomosis, ready availability in most necks and less likely to have configuration problems associated with kinking even when the neck is turned [36]. The external jugular vein is usually less readily available since it is commonly ligated in neck dissections. In preparation for anastomoses, the authors recommend minimal dissection of the IJV, as it tends to be friable and prone for perforations and tears. An option that the authors have the experience of is creating a tunnel down under the skin to the level of the supraclavicular fossa. The availability of the IJV however cannot be guaranteed in the previously operated neck, as noted in a study by Hanaso et al. [25] reporting on the need to seek vessels other than IJV and EJV in 16% cases. The authors are in agreement since we have been in similar situation of not having a patent IJV or the vessel was missing. A composite RFFF or a fibula FF affording good pedicle length may be the only options all these difficult circumstances. If one were compelled to use a deep circumflex iliac artery (DCIA) or scapular flap, the need for vein graft such as the saphenous vein becomes more or less mandatory. Other techniques such as use of the cephalic vein located in the deltopectoral groove and thoracoacromial/cephalic system have been described [33,37]. The perceived advantages include good venous pedicle length and caliber, location outside previous surgery and RT, and the need for a single anastomoses. The authors have no experience in the use of this technique. As described previously in the paper, computed tomographic angiography of the head and neck is invaluable, particularly in previously operated necks to determine the availability of both arterial supply and venous drainage [34,35].

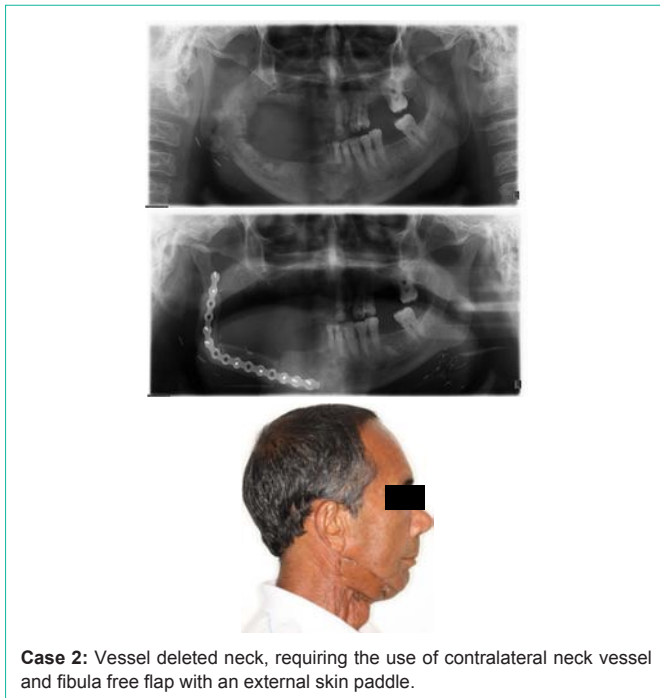
Soft tissues defect and management of the fistula

Oral cavity

The intraoral defect is relatively small in an area of ischaemia and fibrosis. This results in poor healing if primary closure is attempted. A fistula will probably heal if an intra-oral seal is achieved, so often the FF has the primary role of sealing the oral cavity from the neck. Compared to the amount of bone required, soft tissue requirement is often modest. The amount of intraoral soft tissue paddle may be insufficient for clinical evaluation of the free flap perfusion, so the authors recommend the use of implantable Doppler [38]. A DCIA or fibula FFs are quite well suited in these circumstances.

Cutaneous

The extra-oral skin overlying an area of ORN is particularly susceptible to breakdown. Depending on the quality of the external skin, consideration needs to be given to in inside and outside paddle. The external skin can help monitoring the flap. Depending on the



Case 2: Vessel deleted neck, requiring the use of contralateral neck vessel and fibula free flap with an external skin paddle.

availability of neck vessels, the choice of the free flap can be a fibula, DCIA, scapula or composite RFFF.

Neck

Fibrosis of the skin often leads to retraction of the skin, which is further complicated when a subplatysmal skin flap is raised for surgical access. Achieving primary closure at the skin incision site is therefore difficult, if not impossible. This may indicate the need for regular dressings, skin grafts or provision of pedicled flaps or free flaps with a soft tissue component. The authors have experience in avoiding the above scenario by modification to the neck access. A transverse incision in the supraclavicular fossa is made to expose the transverse cervical vessels and lower end of IJV for anastomoses. The pedicle is tunneled through to the supraclavicular fossa to facilitate anastomoses. It should be emphasized that with this technique, the use of a free flap with a long pedicle is mandatory, and potentially rules out the use of DCIA flap. As the oral fistula is frequently small, and neck skin closure is problematic, an alternative used frequently by the authors is to obturate the oral fistula with muscle (flexor hallucis longus with the fibula FF, subscapularis with the scapula FF, internal oblique with the DCIA FF) and the use of skin paddle from the FF in the neck. This allows for easy closure of the neck wound and helps monitoring of the FF viability. The neck skin paddle can be excised six to twelve months post-operatively should it cause cosmetic concerns.

Reconstruction of the bone

The choice of the free flap is mostly influenced by the location of the bone involvement and the availability of the neck vessels, and to a much less extent by the need for soft tissue. For example, whilst a fibula FF may be more ideal for anterior mandibular defects, a DCIA is more suited for posterior defects. Free flaps based on the subscapular vessels [39], although versatile are more suited for large composite defects and will be discussed later in this paper. Bilateral synchronous ORN is fortunately rare, but poses a huge surgical

burden and poor functional outcomes [40]. The authors suggest treatment the most symptomatic side in the first stage and the contralateral side reconstructed at a later date. Every effort should be made to preserve the symphyseal region in bilateral cases of ORN as it is often spared in radiotherapy (e.g. oropharynx) and the muscle attachments on the lingual aspect are best left undisturbed in order to promote better functional outcome. In the absence of suitable composite donor sites or when medical co-morbidities preclude prolonged general anaesthesia, use of a bridging reconstruction plate and a soft tissue free flap or pedicled flap should be considered. Disadvantages include poor aesthetic and functional outcomes and high risk of plate exposure and/or fracture, especially in the dentate jaw. Chepeha et al. [41] have reported a plate exposure rate of 38% and plate fracture rate of 26% in dentulous patients compared with rates of 8% and 6% respectively in edentulous patients. Blackwell et al. [42] reported a delayed reconstructive failure of 40% in patients undergoing lateral mandibular reconstruction with reconstruction plate and soft tissue free flaps and have abandoned their practice in favour of composite free flaps. Wei et al. [43] in their review of 80 patients conclude that reconstruction plate and soft tissue free flap reconstruction of the mandibular defect has many late complications, which eventually necessitate reconstruction with a composite free flap. The authors practice therefore favours the use of composite flaps unless the contraindication is more or less absolute.

Choice of plates

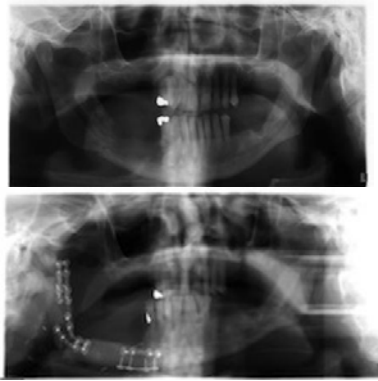
It is customary to use 2.0mm or 2.4mm reconstruction plates for fixation. However, lack of tissue elasticity secondary to fibrosis, combined with inadequate amount of viable bone at the condyle makes access and placement of three screws difficult, if not impossible. The authors have resorted to the use of mini-plates in such circumstances. The use of prefabricated jigs and pre-contoured plates allows for easier moulding and inset of the composite flaps [44]. The locking plates stabilise bone without compression and screws are unlikely to loosen, therefore, potentially there is less bone disruption and less inflammatory response [45,46,47]. Farewell et al. [47] in a retrospective review of 185 vascularised composite reconstructions found no significant difference in complication rates such as plate fracture, exposure, infection or non-union between 2.0mm vs. 2.4mm plates. Shaw et al. [48] in a retrospective analysis of 143 consecutive composite reconstructions found no significant difference between grafts fixed with mini-plates vs. reconstruction plates. Gellrich et al. [49] comparing two types of rigid locking plates showed no statistically significant difference in terms of complications between THORP vs. 2.4mm unlock plates, but have expressed their preference to the use of 2.4mm unlock plates given less bulk.

Choice of flaps

Several factors influence the choice of the free flap such as medical co-morbidities, size and location of the surgical defect, availability of recipient vessels in the neck, availability of suitable donor sites and expertise of the reconstructive surgeon, and the desire for dental rehabilitation [8,39,50,51].

Composite radial forearm free flap

This flap provides pliable skin of a surface area of up to 40cm², and bone length of up to 6-10cm. The thickness of bone available is less than 1.5cm, limited to 40% of the cross-sectional area of the



Case 3: Reconstruction using mini-plates.

radius [50]. Allen's test is routinely carried out to assess the blood flow and in equivocal circumstances, duplex ultrasound of the forearm vessels is indicated. The radial artery is of good calibre. Since the venae comitantes are small, the authors recommend inclusion of the cephalic vein in the flap harvest. This flap can be harvested within reasonable time and affords good pedicle length that can be tunneled to the ipsilateral supraclavicular fossa or the contralateral neck. Disadvantages include poor bone quality that does not support implants, and lack of length if the bone gap is >10cm. Excellent postoperative outcomes with the use of composite RFFF for mandibular reconstruction even in the setting of heavily radiated tissues have been reported in the literature [51]. The authors suggest its use is best limited to posterior mandibular defects or in cases where other composite flaps are contraindicated.

Fibula free flap

The fibula can be harvested as a free osseous or a free osseocutaneous flap. Despite concerns about the reliability of the skin paddle, the authors have not found this to be a problem, and there is now improved understanding of the skin perforator anatomy of the fibula [52]. Up to 25cm of bone can be harvested. The peroneal artery maintains a good calibre through its course along the bone accompanied by paired voluminous venae comitantes. The pedicle length can be increased to as long as 12cm by harvesting a more distal segment of bone while discarding the more proximal fibula. The authors advocate the routine use of pre-operative MR or CT-angiography to rule out atherosclerotic disease or a dominant peroneal artery. These investigations may also contribute to safer placement of the bone cuts [53]. The long pedicle length allows ipsilateral anastomoses to the transverse cervical vessels or contralateral vessels. The large caliber venae comitantes are a poor size match to veins other than EJV and IJV. Lack of bone height is not a major issue in an edentulous jaw. In the dentate jaw, this problem can be overcome by double barrel technique or fixation of the fibula at the level of the occlusal plane. Although the use of double-barrel fibula free flap for better aesthetics and bone height for osseointegrated implants is well documented in the literature [39], the authors do not recommend this technique in the reconstruction of the ORN defect.

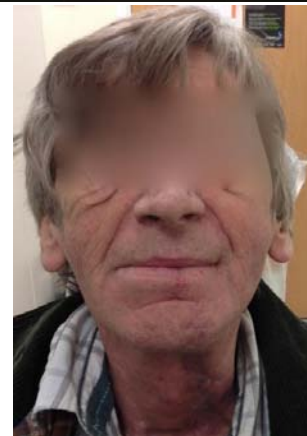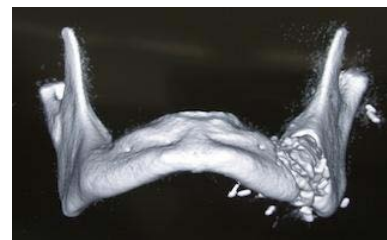Deep circumflex iliac artery free flap

This flap provides a large concave segment of cancellous bone, up to 16cm long and 6cm height. The arterial calibre is 1.5-3mm,

accompanied by a slightly larger calibre vein. The pedicle can be up to 7cm in length depending on the size and position bone segment. The relation of the skin paddle to the bone is somewhat fixed and the reliability of the pedicle has been questioned since there are conflicting reports on the location and number of perforators [54]. The bone may be osteotomised and contoured to match various defects, both in the symphyseal and posterior segments of the mandible. The mandatory cuff of internal oblique muscle is excellent for obturating the intraoral soft tissue defect and the fistula. Also, the denervated muscle will atrophy and mucosalise over time, an added benefit should implants be considered at a later stage. If skin paddle is used, debulking at a later stage is often necessary. The harvest of this flap requires can be challenging and time consuming, hence careful consideration should be given. Complications include hernia and impact mobility; hence social circumstances should be considered [55].

Subscapular system of flaps

The subscapular system of flaps is unique among all free flap donor sites because of the reliability, diversity of tissue type, potential surface area that can be transferred and the mobility of the soft tissue component in relation to the bone. There is no need for any flap related workup and the donor site morbidity is minimal. The relative sparing of scapular vessels from atherosclerotic disease makes them an excellent choice when a fibular free flap is contraindicated [56]. The flap may be raised in a chimeric fashion. The lateral border of the scapula can be included based on the transverse branch or the angle of the scapula included based on the angular branch of the circumflex scapular artery. The pedicle length can extend up to 10cm in when harvested on the angular branch. The subscapular system free flaps are excellent options for elderly patients, those with significant comorbidities, such as peripheral vascular disease and mandible defects associated with complex soft-tissue requirements and



Case 4: Good aesthetic outcome following fibula free flap reconstruction of a Notani grade III defect.

segmental defects of the angle of the mandible [57]. The authors have required the use of these flaps on selected few occasions only since the requirement for soft tissue is often minimal in the ORN patient and the harvest is time consuming, especially the need for prone positioning of the patient, which may be circumvented by using a lateral approach.

Expertise of the unit

Best management of the ORN patient requires an experienced reconstructive surgeon leading a multidisciplinary team comprising a dedicated anaesthetist, ITU support, specialist ward, and allied specialists. The surgeon should be experienced in the harvest of the flaps discussed in the preceding section. Support from other surgical colleagues, for example cardio-thoracic surgeons may be required in selected cases to expose the internal mammary vessels.

Outcomes

The published literature reports high success rates in excess of 95% following FF reconstruction and its positive influence on the QOL of patients with ORN [40,58,59]. Surgical complications such as wound infection, skin necrosis, salivary fistula, partial flap loss and in rare instances, carotid blow-out range from 21-56% [59,60-62].

Militshak et al. [51] have reported on the successful restoration of mandibular integrity and continuity, with 100% success rate of stabilization of ORN following reconstruction composite radial forearm flap. In a retrospective review by Suh et al. [60], of 40 patients with mandibular ORN treated with segmental mandibulectomy and FF, 25% developed recurrent ORN, with 70% of the recurrences arising in the unresected condyles. In a review of 37 patients by Sawhney et al. [61], 95% patients returned to pre-fracture dietary intake following FF reconstruction. Baumann et al. [62] reporting on 75 patients who underwent FF reconstruction showed that, a full oral diet was tolerated in 57% patients, whereas 26% required partial tube feeding, and 16% were tube-dependent feeding. In another study [51], all patients tolerated oral diet, only one-third having to supplement diet with gastrostomy feeding, compared with 89% gastrostomy dependence prior to FF reconstruction. In a QOL study of outcomes in patients after reconstruction with fibula using UWQOLv4 questionnaire by Wang et al. [63], the best scoring domain was pain and more than 70% patients perceived improved HR-QOL after reconstruction.

Conclusion

Advanced ORN is a debilitating condition and requires prompt management. The needs of the patients are complex and require multidisciplinary approach, led by an experienced reconstructive surgeon. The importance of pre-operative workup with involvement of specialist physicians, anaesthetists, primary care and nutritional specialists all working in close liaison is important. Surgery is indicated for severe pain not effectively managed by opiates, fistula formation, trismus and poor quality of life. In spite of radical treatment, the outcomes tend to support surgical intervention as these problems can be adequately addressed.

In summary, from the past experience and studies, it is clear that medical optimization and MDT approach is mandatory in the management of all patients with ORN. The choice of flap should be based on: 1. The availability and the quality of recipient vessels

for anastomosis. 2. The amount of bone and soft tissue required. 3. Length of pedicle and caliber of the vessels at the free flap donor site.

References

- Harris M. The conservative management of osteoradionecrosis of the mandible with ultrasound therapy. *Br J Oral Maxillofac Surg.* 1992; 30: 313-318.
- Clayman L. Clinical controversies in oral and maxillofacial surgery: Part two. Management of dental extractions in irradiated jaws: a protocol without hyperbaric oxygen therapy. *J Oral Maxillofac Surg.* 1997; 55: 275-281.
- Wahl MJ. Osteoradionecrosis prevention myths. *Int J Radiat Oncol Biol Phys.* 2006; 64: 661-669.
- Balogh JM, Sutherland SE. Osteoradionecrosis of the mandible: a review. *J Otolaryngol.* 1989; 18: 245-250.
- Urken ML, Weinberg H, Buchbinder D, Moscoso JF, Lawson W, Catalano PJ, et al. Microvascular free flaps in head and neck reconstruction. Report of 200 cases and review of complications. *Arch Otolaryngol Head Neck Surg.* 1994; 120: 633-640.
- Yazar S, Wei FC, Chen HC, Cheng MH, Huang WC, Lin CH, et al. Selection of recipient vessels in double free-flap reconstruction of composite head and neck defects. *Plast Reconstr Surg.* 2005; 115: 1553-1561.
- Katsura K, Sasai K, Sato K, Saito M, Hoshina H, Hayashi T. Relationship between oral health status and development of osteoradionecrosis of the mandible: a retrospective longitudinal study. *Oral Surg Oral Med Oral Pathol Oral Radiol Endod.* 2008; 105: 731-738.
- Goldwaser BR, Chuang SK, Kaban LB, August M. Risk factor assessment for the development of osteoradionecrosis. *J Oral Maxillofac Surg.* 2007; 65: 2311-2316.
- Kheterpal S, O'Reilly M, Englesbe MJ, Rosenberg AL, Shanks AM, Zhang L, et al. Preoperative and intraoperative predictors of cardiac adverse events after general, vascular, and urological surgery. *Anesthesiology.* 2009; 110: 58-66.
- National Confidential Enquiry into Patient Outcome and Death.
- Tønnesen H, Nielsen PR, Lauritzen JB, Møller AM. Smoking and alcohol intervention before surgery: evidence for best practice. *Br J Anaesth.* 2009; 102: 297-306.
- Correia MI, Waitzberg DL. The impact of malnutrition on morbidity, mortality, length of hospital stay and costs evaluated through a multivariate model analysis. *Clin Nutr.* 2003; 22: 235-239.
- Bertrand PC, Piquet MA, Bordier I, Monnier P, Roulet M. Preoperative nutritional support at home in head and neck cancer patients: from nutritional benefits to the prevention of the alcohol withdrawal syndrome. *Curr Opin Clin Nutr Metab Care.* 2002; 5: 435-440.
- Hughes BG, Jain VK, Brown T, Spurgin AL, Hartnett G, Keller J, et al. Decreased hospital stay and significant cost savings after routine use of prophylactic gastrostomy for high-risk patients with head and neck cancer receiving chemoradiotherapy at a tertiary cancer institution. *Head Neck.* 2012; 13: 436-442.
- Goodnough LT, Shander A, Spivak JL, Waters JH, Friedman AJ, Carson JL, et al. Detection, evaluation, and management of anemia in the elective surgical patient. *Anesth Analg.* 2005; 101: 1858-1861.
- Poldermans D, Bax JJ, Boersma E, De Hert S, Eeckhout E, Fowkes G, et al. Guidelines for pre-operative cardiac risk assessment and perioperative cardiac management in non-cardiac surgery. The Task Force for Preoperative Cardiac Risk Assessment and Perioperative Cardiac Management in Non-cardiac Surgery of the European Society of Cardiology and endorsed by the European Society of Anaesthesiology *Eur J Anaesthesiol.* 2010; 27: 92-137.
- Davies SJ, Wilson RJ. Preoperative optimization of the high-risk surgical patient. *Br J Anaesth.* 2004; 93: 121-128.
- Doenst T, Wijeyesundera D, Karkouti K, Zechner C, Maganti M, Rao V, et al. Hyperglycemia during cardiopulmonary bypass is an independent risk factor

- for mortality in patients undergoing cardiac surgery. *J Thorac Cardiovasc Surg.* 2005; 130: 1144.
19. Halaszynski TM, Juda R, Silverman DG. Optimizing postoperative outcomes with efficient preoperative assessment and management. *Crit Care Med.* 2004; 32: S76-86.
 20. Urken ML, Higgins KM, Lee B, Vickery C. Internal mammary artery and vein: recipient vessels for free tissue transfer to the head and neck in the vessel-depleted neck. *Head Neck.* 2006; 28: 797-801.
 21. Wong KK, Higgins KM, Enepekides DJ. Microvascular reconstruction in the vessel-depleted neck. *Curr Opin Otolaryngol Head Neck Surg.* 2010; 18: 223-226.
 22. Gujral DM, Shah BN, Chahal NS, Senior R, Harrington KJ, Nutting CM. Clinical features of radiation-induced carotid atherosclerosis. *Clin Oncol (R Coll Radiol).* 2014; 26: 94-102.
 23. Dubec JJ, Munk PL, Tsang V, Lee MJ, Janzen DL, Buckley J, et al. Carotid artery stenosis in patients who have undergone radiation therapy for head and neck malignancy. *Br J Radiol.* 1998; 71: 872-875.
 24. Zaghi S, Danesh J, Hendzadeh L, Nabili V, Blackwell KE. Changing indications for maxillomandibular reconstruction with osseous free flaps: a 17-year experience with 620 consecutive cases at UCLA and the impact of osteoradionecrosis. *Laryngoscope.* 2014; 124: 1329-1335.
 25. Hanasono MM, Barnea Y, Skoracki RJ. Microvascular surgery in the previously operated and irradiated neck. *Microsurgery.* 2009; 29: 1-7.
 26. Head C, Sercarz JA, Abemayor E, Calcaterra TC, Rawnsley JD, Blackwell KE. Microvascular reconstruction after previous neck dissection. *Arch Otolaryngol Head Neck Surg.* 2002; 128: 328-331.
 27. Knoetgen J 3rd, Choudry U, Finical SJ, Johnson CH. Head and neck reconstruction with a second free flap following resection of a recurrent malignancy. *Ann Plast Surg.* 2005; 55: 378-383.
 28. Nakayama B, Kamei Y, Toriyama K, Hyodo I, Hasegawa Y, Torii S. Usefulness of a first transferred free flap vascular pedicle for secondary microvascular reconstruction in the head and neck. *Plast Reconstr Surg.* 2002; 109: 1246-1253.
 29. Yu P. The transverse cervical vessels as recipient vessels for previously treated head and neck cancer patients. *Plast Reconstr Surg.* 2005; 115: 1253-1258.
 30. Aycock JK, Stenson KM, Gottlieb LJ. The thoracoacromial trunk: alternative recipient vessels in reoperative head and neck reconstructive microsurgery. *Plast Reconstr Surg.* 2008; 121: 88-94.
 31. Dolan R, Gooley J, Cho YJ, Fuleihan N. Microvascular access in the multiply operated neck: thoracodorsal transposition. *Laryngoscope.* 1996; 106: 1436-1437.
 32. Miller MJ, Schusterman MA, Reece GP, Kroll SS. Interposition vein grafting in head and neck reconstructive microsurgery. *J Reconstr Microsurg.* 1993; 9: 245-251.
 33. Harris JR, Lueg E, Genden E, Urken ML. The thoracoacromial/cephalic vascular system for microvascular anastomoses in the vessel-depleted neck. *Arch Otolaryngol Head Neck Surg.* 2002; 128: 319-323.
 34. Kramer M, Nkenke E, Kikuchi K, Schwab SA, Janka R, Uder M, et al. Whole-body magnetic resonance angiography for presurgical planning of free-flap head and neck reconstruction. *Eur J Radiol.* 2012; 81: 262-266.
 35. Kramer M, Schwab SA, Nkenke E, Eller A, Kammerer F, May M, et al. Whole body magnetic resonance angiography and computed tomography angiography in the vascular mapping of head and neck: an intra-individual comparison. *Head Face Med.* 2014; 10: 16.
 36. Halvorson EG, Cordeiro PG. Go for the jugular: a 10-year experience with end-to-side anastomosis to the internal jugular vein in 320 head and neck free flaps. *Ann Plast Surg.* 2007; 59: 31-35.
 37. Kim KA, Chandrasekhar BS. Cephalic vein in salvage microsurgical reconstruction in the head and neck. *Br J Plast Surg.* 1998; 51: 2-7.
 38. Ho MW, Cassidy C, Brown JS, Shaw RJ, Bekiroglu F, Rogers SN. Rationale for the use of the implantable Doppler probe based on 7 years' experience. *Br J Oral Maxillofac Surg.* 2014; 52: 530-534.
 39. Ch'ng S, Ashford BG, Clark JR. Alignment of the double-barrel fibula free flap for better cosmesis and bone height for osseointegrated dental implants. *Plast Reconstr Surg.* 2013; 132: 688e-689e.
 40. Reiffel AJ, Rohde CH, Kutler DI, Spector JA. Sequential second free fibula flap for the reconstruction of metachronous osteoradionecrosis of the mandible. *J Craniofac Surg.* 2012; 23: e90-91.
 41. Chepeha DB, Teknos TN, Fung K, Shargorodsky J, Sacco AG, Nussenbaum B, et al. Lateral oromandibular defect: when is it appropriate to use a bridging reconstruction plate combined with a soft tissue vascularized flap. *Head Neck.* 2008; 30: 709-717.
 42. Blackwell KE, Buchbinder D, Urken ML. Lateral mandibular reconstruction using soft-tissue free flaps and plates. *Arch Otolaryngol Head Neck Surg.* 1996; 122: 672-678.
 43. Wei FC, Celik N, Yang WG, Chen IH, Chang YM, Chen HC. Complications after reconstruction by plate and soft-tissue free flap in composite mandibular defects and secondary salvage reconstruction with osteocutaneous flap. *Plast Reconstr Surg.* 2003; 112: 37-42.
 44. Saad A, Winters R, Wise MW, Dupin CL, St Hilaire H. Virtual surgical planning in complex composite maxillofacial reconstruction. *Plast Reconstr Surg.* 2013; 132: 626-633.
 45. Knott PD, Suh JD, Nabili V, Sercarz JA, Head C, Abemayor E, et al. Evaluation of hardware-related complications in vascularized bone grafts with locking mandibular reconstruction plate fixation. *Arch Otolaryngol Head Neck Surg.* 2007; 133: 1302-1306.
 46. Militsakh ON, Wallace DI, Kriet JD, Girod DA, Olvera MS, Tsue TT. Use of the 2.0-mm locking reconstruction plate in primary oromandibular reconstruction after composite resection. *Otolaryngol Head Neck Surg.* 2004; 131: 660-665.
 47. Farwell DG, Kezirian EJ, Heydt JL, Yueh B, Futran ND. Efficacy of small reconstruction plates in vascularized bone graft mandibular reconstruction. *Head Neck.* 2006; 28: 573-579.
 48. Shaw RJ, Kanatas AN, Lowe D, Brown JS, Rogers SN, Vaughan ED. Comparison of miniplates and reconstruction plates in mandibular reconstruction. *Head Neck.* 2004; 26: 456-463.
 49. Gellrich NC, Suarez-Cunqueiro MM, Otero-Cepeda XL, Schön R, Schmelzeisen R, Gutwald R. Comparative study of locking plates in mandibular reconstruction after ablative tumor surgery: THORP versus UniLOCK system. *J Oral Maxillofac Surg.* 2004; 62: 186-193.
 50. Kim JH, Rosenthal EL, Ellis T, Wax MK. Radial forearm osteocutaneous free flap in maxillofacial and oromandibular reconstructions. *Laryngoscope.* 2005; 115: 1697-1701.
 51. Militsakh ON, Wallace DI, Kriet JD, Tsue TT, Girod DA. The role of the osteocutaneous radial forearm free flap in the treatment of mandibular osteoradionecrosis. *Otolaryngol Head Neck Surg.* 2005; 133: 80-83.
 52. Winters HA, de Jongh GJ. Reliability of the proximal skin paddle of the osteocutaneous free fibula flap: a prospective clinical study. *Plast Reconstr Surg.* 1999; 103: 846-849.
 53. Garvey PB, Chang EI, Selber JC, Skoracki RJ, Madewell JE, Liu J, et al. A prospective study of preoperative computed tomographic angiographic mapping of free fibula osteocutaneous flaps for head and neck reconstruction. *Plast Reconstr Surg.* 2012; 130: 541e-549e.
 54. Bergeron L, Tang M, Morris SF. The anatomical basis of the deep circumflex iliac artery perforator flap with iliac crest. *Plast Reconstr Surg.* 2007; 120: 252-258.
 55. Ling XF, Peng X, Samman N. Donor-site morbidity of free fibula and DCIA flaps. *J Oral Maxillofac Surg.* 2013; 71: 1604-1612.
 56. Hasan Z, Gore SM, Ch'ng S, Ashford B, Clark JR. Options for configuring the scapular free flap in maxillary, mandibular, and calvarial reconstruction. *Plast Reconstr Surg.* 2013; 132: 645-655.

57. Douthwaite SA, Theurer J, Belzile M, Fung K, Franklin J, Nichols A, et al. Comparison of fibular and scapular osseous free flaps for oromandibular reconstruction: a patient-centered approach to flap selection. *JAMA Otolaryngol Head Neck Surg.* 2013; 139: 285-292.
58. Chang DW, Oh HK, Robb GL, Miller MJ. Management of advanced mandibular osteoradionecrosis with free flap reconstruction. *Head Neck.* 2001; 23: 830-835.
59. Hirsch DL, Bell RB, Dierks EJ, Potter JK, Potter BE. Analysis of microvascular free flaps for reconstruction of advanced mandibular osteoradionecrosis: a retrospective cohort study. *J Oral Maxillofac Surg.* 2008; 66: 2545-2556.
60. Suh JD, Blackwell KE, Sercarz JA, Cohen M, Liu JH, Tang CG, et al. Disease relapse after segmental resection and free flap reconstruction for mandibular osteoradionecrosis. *Otolaryngol Head Neck Surg.* 2010; 142: 586-591.
61. Sawhney R, Ducic Y. Management of pathologic fractures of the mandible secondary to osteoradionecrosis. *Otolaryngol Head Neck Surg.* 2013; 148: 54-58.
62. Baumann DP, Yu P, Hanasono MM, Skoracki RJ. Free flap reconstruction of osteoradionecrosis of the mandible: a 10-year review and defect classification. *Head Neck.* 2011; 33: 800-807.
63. Wang L, Su YX, Liao GQ. Quality of life in osteoradionecrosis patients after mandible primary reconstruction with free fibula flap. *Oral Surg Oral Med Oral Pathol Oral Radiol Endod.* 2009; 108: 162-168.